

## EFFECT OF DORAMECTIN ON FOETAL DEVELOPMENT IN RATS

Amer, M. S.; Gabr, M. G.; Gad, G. N.\*

and Abd El-Gallil, R.

Pharmacology Department, Faculty of Veterinary Medicine,  
Mansoura University, Egypt.\*Animal Health Research Institute, Zagazig, Egypt.

### ABSTRACT

*Doramectin (25-cyclohexyl-5-O-demethyl- 25-de(1-methylpropyl) avermectin A1a), is a member of the Macrocyclic lactones family. Macrocyclic lactones are major commercial antiparasitic agents in the field of animal health, agriculture, and human infections. Their remarkable broad spectrum activity against a variety of nematode and arthropod parasites and their safety profile put these drugs at the cornerstone of modern anthelmintic therapy in livestock. From this view, The toxicity of doramectin was tested in female rat and their foeti. The study was applied on thirty female mature rats divided into three groups, 1<sup>st</sup> group was kept as control (injected sesame oil s.c.), while the 2<sup>nd</sup> group was injected s.c. by the therapeutic dose of doramectin (0.2 mg/kg b.wt.), meanwhile the 3<sup>rd</sup> group was injected s.c. by the double dose of doramectin (0.4 mg/kg b.wt.). Teratological examination and chromosomal aberrations examination were the parameters used in this study. The results showed that the therapeutic dose of doramectin is relatively safe but the double dose induced visceral malformations and chromosomal aberrations. So we must increase the attention paid to the corrective dose of the drug especially in pregnant animals and should stress the need for careful control to ensure adherence to the prescribed withdrawal time of this drug.*

**Key words:** *macrocyclic lactones / doramectin / genotoxicity / teratogenicity.*

### INTRODUCTION

In recent years, there has been widespread and increasing concern that drugs, as well as environmental chemicals, may present a potential hazard to mankind by developmental malformations and chromosomal aberrations.

Macrocyclic lactones are major commercial antiparasitic agents in the field of animal

health. Their remarkable broad spectrum activity and their safety profile put these drugs at the cornerstone of modern anthelmintic therapy in livestock (Molyneux et al., 2003). Doramectin, a new 'endectocide', effective against intestinal round worms and external parasites. Based on its antinematodal activity in vitro, and in laboratory models and in cattle, doramectin was selected as the best of a series of novel avermectins for development as

a livestock endectocides (Jayakumar et al. 1999).

Some members of this class of drugs have teratogenic and embryotoxic effects in animal species. Rats given ivermectin during the early stage of pregnancy revealed deaths in embryos and teratogenic changes in the foeti of the treated rats during the late stage of pregnancy (Tuchman-Duplessis, 1975; and Ali et al., 1988). Subcutaneous administration of the therapeutic dose of ivermectin, given prenatal, provoked a high incidence of neonatal mortality coupled with a marked retardation in their growth (Poul, 1988 and Lankas et al., 1989). Abamectin produced cleft palate in the offspring of treated mice and rabbits, but only at doses that were also toxic to the mothers (Lankas and Gordon, 1989).

So the purpose of the present study was to evaluate the effect of doramectin on the incidence of genetic alteration in female rats and their teratogenic effect in embryos of treated dams

## 2. MATERIALS AND METHODS

### 2.1. Drug :

Dectomax (Pfizer Inc., New York, NY, USA) 25-cyclohexyl -5-O-demethyl -25-de (1-methylpropyl) avermectin A1a, Each vial contains the equivalent of one gram semi-synthetic doramectin. Dectomax is a sterile 1% injectable solution of doramectin in a sesame oil-ethyl oleate (90:10 v/v) vehicle. For preparation of rat dose, the drug diluted in sesame oil. Dectomax is administered to cattle at a dose rate of 0.2 mg/kg b.wt.. The rat dose; 5 ug/200gm was determined according to paget and Barnes (1964).

### 2.2. Experimental design :

The effects of doramectin on foetal development were investigated on thirty Mature female albino rats, using fifteen mature male albino rats for mating. animals were kept under hygienic conditions housed in metal cages. fed on a balanced ration and watered ad libidum. They were accommodated to the laboratory conditions for two weeks before experimentation.

Daily vaginal smears were examined and the female proved to be in oestrus was paired with a male in a separate cage. In the following morning a vaginal smear was taken to verify the first day of gestation. Presence of sperms in the obtained vaginal smear indicates zero day of gestation (Barcelona et al., 1977). Pregnancy was confirmed by microscopic examination of vaginal smears, presence of permanent dioestrus indicated pregnancy. Body weight was recorded and prominent increases were observed chiefly after ten days from the expected day of pregnancy (Cohen, 1966). The pregnant rats were divided into three equal groups each of ten.

**Group I :** received sesame oil subcutaneously, at 6th day of gestation as a control group.

**Group II :** received therapeutic dose of doramectin 0.2 mg/kg b.wt subcutaneously, at 6th day of gestation.

**Group III :** received double dose of doramectin 0.4 mg/kg b.wt subcutaneously, at 6th day of gestation.

Doramectin was injected at 6<sup>th</sup> day of gestation period during which the organs are more sensitive to the effect of the toxic substances (Snell, 1982). The possible effects of

the therapeutic dose and the double dose of doramectin on developing foeti were evaluated by morphological, visceral, skeletal, and cytogenetic examination.

#### **Effects of doramectin on neonates during suckling period :**

Determination of the chromosomal aberrations in neonates naturally delivered from pregnant rat administered therapeutic regimen of doramectin; 0.2 mg/kg B.wt. subcutaneously. The experiment was studied on fifteen, 3-4 month old, female albino rats and seven, 4-5 month old, male albino rats.

After detection of pregnancy, the pregnant rats were divided into three equal groups of each five .

The first group received sesame oil subcutaneously, at the day of parturition as a control group.

The second group received therapeutic dose of doramectin before parturition.

The third group received therapeutic dose of doramectin at the day of parturition.

#### **2.3. Teratological examination**

On day 20 of gestation period, all pregnant females from each group were sacrificed, the uterine horns were opened and The number of implantation and resorption sites were counted as described by (Kopf and Salewski, 1964).

The number of live and dead foeti, foetal body weight and foetal crown-rump length were recorded. The foeti were examined for

any gross external malformations. Pre and post-implantation deaths were calculated according to Hayes (1988). Foeti preserved in Bouin's fixative were rinsed with cold water and examined grossly. Stained skeletons with alizarin red stain were examined by a hand lens for any abnormalities in shape or size or absence of bones .

#### **2.4. Chromosome preparation**

It was carried out according to (Yosida and Amano, 1965). colchicine's solution; 0.5% was intramuscularly injected at a dose of 0.25% ml/100gm B.wt Into rat groups before sacrificed by ninety minutes in order to increase the mitotic cell number. Chromosomes were stained by Giemsa stain according to Genest and Auger (1963). then were examined under the maximum magnification using the oil immersion lens for details.

#### **2.5. Statistical analysis:**

Data analyses were performed with statistical software program (SPSS) (ANOVA).. The mean values and standard deviation for each assessed variable were calculated.

## **RESULTS**

#### **1. Effects on developing foeti :**

The mean values of the different teratogenic variables are tabulated in Table (1) and Figures (1-3). The results showed that the administration of the therapeutic dose of doramectin at 6<sup>th</sup> day of gestation period evoked insignificant increase in foetal resorption rate, While dams administered double dose of doramectin at 6<sup>th</sup> day of gestation period displayed a significant increase in foetal resorption rate, versus the control group. The obtained data clearly demonstrate that the

double dose of doramectin provoked insignificant decrease in the mean values of the viable foeti. Where the therapeutic dose elicited insignificant changes in the mean values of the viable foeti, compared with the control group. Dams given the therapeutic dose of doramectin at 6th day of gestation period showed insignificant increase in the mean values of the dead foeti, and the double dose displayed insignificant increase in the mean values of the dead foeti, versus in the control group. Administration of the therapeutic dose and the double dose of doramectin at 6th day of gestation period evoked insignificant changes in the mean values of pre-implantation post-implantation death compared with the control group.

### 2- Morphological examination:

The obtained data clearly demonstrate that the therapeutic dose of doramectin induced insignificant changes in the mean values of the body weight and foetal crown-rump length of the obtained foeti, but the double dose induced a significant decrease in the mean values of the body weight and foetal crown-rump length of the obtained foeti compared with the control group.

### 2- Visceral examination:-

Foeti obtained from the treated and control groups were kept in Bouin's solution. Subcutaneous injection of the double dose of doramectin elicited visceral abnormalities evidenced by hemorrhage in the brain, thickening of the ventricular wall of the heart, and slight unilateral or bilateral widening of the renal pelvis, but therapeutic dose evoked slight abnormalities in kidney and heart (Table 2) and ( figure 2).

### 3- Skeletal examination :-

Allizarin red stained skeletons of the rat foeti obtained from all groups treated with both therapeutic or double dose of doramectin and control dams showing no skeletal malformations (figure 2).

## II. Cytogenetic effects :

### Dams:-

Chromosomal aberrations recorded in pregnant rats injected with the therapeutic and double doses of doramectin at 6th day of gestation period were clearly demonstrated in Table (3) and Figures (3). Pregnant rats administered the therapeutic dose of doramectin displayed insignificant change in the mean values of total chromosomal aberrations compared with the control group. The double dose of the drug elicited a highly significant increase ( $P < 0.001$ ) in the mean values of total chromosomal aberrations where the structural aberrations recorded were ring chromosomes, chromatid and chromosomal breaks, gap, deletion, sticky chromosomes, end to end association, fragment and pulverized chromosomes, in addition to hypoploidy as numerical abnormality.

### Foeti :-

Table (4) revealed the mean values of total chromosomal aberrations, in suckling neonates naturally delivered from female rats given therapeutic dose of doramectin at 6<sup>th</sup> day of gestation period (pre-parturition) and at 1<sup>st</sup> day of parturition (post-parturition). Both groups evoked insignificant change in the mean values of total chromosomal aberrations,  $12.05 \pm 0.50$  with 2.4% and  $11.50 \pm 0.34$  with 2.2% respectively compared with,  $11.1 \pm 0.23$  with 2% for the control group

### DISCUSSION

Doramectin, a new 'endectocide' effective against intestinal round worms and external parasites. Based on antinematodal activity *in vitro*, and in laboratory models and in cattle, doramectin was selected as the best of a series of novel avermectins for development as a livestock endectocides (Jayakumar et al., 1999). In the present study the results showed that the administration of the therapeutic dose of doramectin at 6th day of gestation period evoked insignificant increase in foetal resorption rate. While dams administered double dose of doramectin at 6th day of gestation period displayed a significant increase in foetal resorption rate. This results were in agreement with, (Tuchman-Duplessis, 1975; and Ali et al., 1988) reported that rats given ivermectin during the early stage of pregnancy revealed deaths in embryos and teratogenic changes in the foeti of the treated rats during the late stage of pregnancy. Persaud and Henderson (1969) provided attractive clues for foetal resorptions. The authors reported that during the first twelve days of embryonic development, certain teratogenes may kill the embryo by damaging all or most of its cells by preventing implantation of the blastocyst or by producing several chromosomal changes and consequently its resorption.

The obtained data clearly demonstrate that the therapeutic dose of doramectin induced insignificant changes in the mean values of the body weight and the crown rump length of the obtained foeti, but the double dose induced a significant decrease in the mean values of the body weight and the crown-rump length of the obtained foeti. It is a fact that the foetal body weight and the crown-rump

length faithfully echo the foetal development and neonatal mortality coupled with the concept that chromosomal abnormalities induced by many chemicals affect cellular DNA and consequently the foetal growth (Lubchenco, 1970). Given this background, it is tempting to suggest that the decreased foetal body weight and length is a forthright outcome of the chromosomal abnormalities reported in the present study.

In the present study, it has been shown that, the most frequently encountered discernible visceral malformation in the foeti obtained from dams injected with both therapeutic and double dose of the drug thickening of the ventricular wall of the heart and slight unilateral or bilateral widening of the renal pelvis. Our results were in agreement with Gad G. N., (1992) who documented that, the most frequently encountered discernible internal malformations in response to ivermectin injection at a dose of 0.2 and 0.4 mg/ kg B.wt. were: cleft palate, thickening of the ventricular wall of the heart, haemorrhage around brain and dilatation of renal pelvis.

In the present study pregnant rats administered the therapeutic dose of doramectin displayed insignificant change in the mean values of total chromosomal aberrations compared with the control group. The double dose of the drug elicited a highly significant increase in the mean values of total chromosomal aberrations where the structural aberrations recorded were ring chromosomes Chromatid and chromosomal breaks, gap, deletion, sticky chromosomes, end to end association, fragment and pulverized chromosomes, in addition to hypoploidy as numerical

abnormality. This agree with (Gad G. N. 1992) where found that, the therapeutic use of ivermectin injected subcutaneously on the

organogenesis period provoked chromosomal aberrations a marked prolongation of gestation period up to 28 days.

**Table (1) :** Morphological changes and mortality rate in foeti from dam rats subcutaneously injected with the therapeutic dose of doramectin 0.2 mg/kg b.wt and double dose 0.4 mg/kg b.wt at 6<sup>th</sup> day of gestation period. (Mean  $\pm$  S.E) n=10

Group	No. of corpora lutea	No. of implantation sites	Viable foeti		Dead foeti		Resorbed foeti		Foetal b.wt. (gm)	Foetal length (cm)	Death	
			Mean $\pm$ S.E	%	Mean $\pm$ S.E	%	Mean $\pm$ S.E	%			Pre-implantation	Post-implantation
control	8.80 $\pm$ 0.36	7.70 $\pm$ 0.42	7.50 $\pm$ 0.40	98.75 $\pm$ 0.25	0.0 $\pm$ 0.0	0.0 $\pm$ 0.0	0.20 $\pm$ a 0.13	2.5 $\pm$ 0.43	4.1 $\pm$ a 0.35	4.0 $\pm$ a 0.24	0.11 $\pm$ 0.044	0.02 $\pm$ 0.013
Therapeutic dose	8.70 $\pm$ 0.37	7.20 $\pm$ 0.47	7.04 $\pm$ 0.65	97.5 $\pm$ 0.35	0.1 $\pm$ 0.01	1.3 $\pm$ 0.35	0.50 $\pm$ a 0.22	6.94 $\pm$ 0.55	4.0 $\pm$ a 0.25	3.99 a 0.29	0.15 $\pm$ 0.058	0.05 $\pm$ 0.030
Double dose	8.69 $\pm$ 0.54	7.10 $\pm$ 0.59	6.06 $\pm$ 0.52	75.22 $\pm$ 0.21	0.2 $\pm$ 0.13	2.27 $\pm$ 0.15	12.5 $\pm$ 0.14				0.14 $\pm$ 0.048	0.25 $\pm$ 0.057

**Table (2):** Visceral malformations in foeti from dam rats subcutaneously injected with the therapeutic dose of doramectin 0.2 mg/kg b.wt and double dose 0.4 mg/kg b.wt at 6<sup>th</sup> day of gestation period.

Group	Total		Malformations						
	Number	Normal		Heart		Kidney		Liver	
		Pro.	%	No.	%	No.	%	No.	%
Control	29	--	0.0	--	0.0	--	0.0	--	0.0
Therapeutic dose	26	--	0.0	--	0.0	2	7.7	1	3.84
Double dose	23	--	0.0	2	8.7	5	21.74	6	26.1




Table (3) : Cytogenetic effects of subcutaneous administration of therapeutic dose of doramectin 0.2 mg/kg b wt and double dose 0.4 mg/kg b.wt at 6<sup>th</sup> day of gestation period (Mean  $\pm$  S.E.) n=10


Group	No. of examined metaphase cells	Types of aberrations													Total damage		
		Structural						Centeromeric				Numerical			%	Mean $\pm$ S.E.	
		Ring	Breaks	Gap	Deletion	Stick	End to end association	Fragment	Centeromeric attenuation	Pulverized	Hypoploidy	Polyploidy	No.				
control	500	--	--	1	2	2	3	--	--	--	2	--	2	--	10	2	10.60 $\pm$ 0.34
a	500	--	1	--	3	1	2	--	--	2	--	4	--	13	2.6	13.80 $\pm$ 0.39	
b	500	4	4	2	9	4	3	3	3	3	1	10	--	43	8.6		

Table (4) : Cytogenetic effects in suckling neonates naturally delivered from female rats given therapeutic dose of doramectin 0.2 mg/kg b.wt subcutaneously at 6<sup>th</sup> day of gestation period (a) and at 1<sup>st</sup> day of parturition (b) (Mean  $\pm$  S.E.) n=10

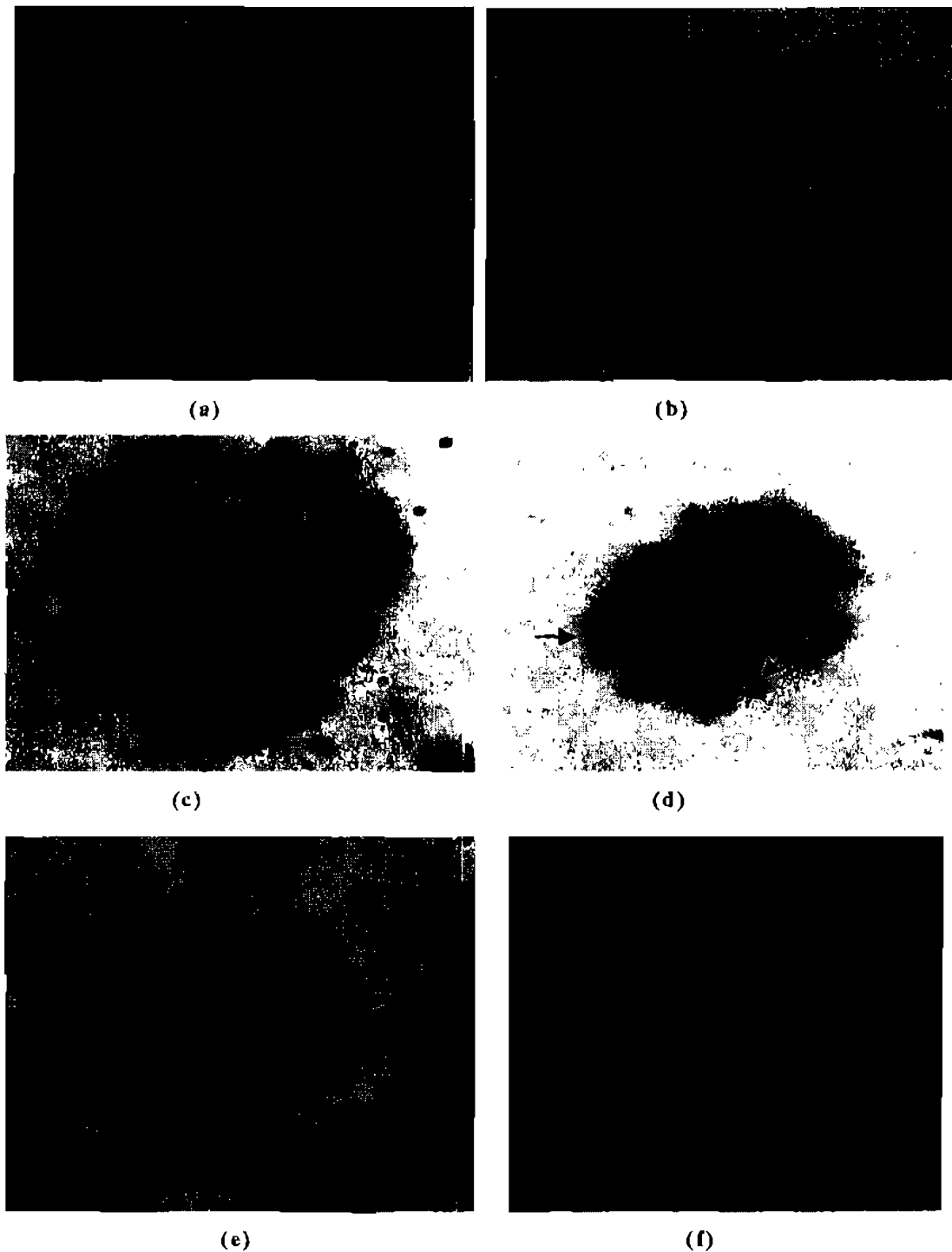
Group	No. of examined metaphase cells	Types of aberrations													Total damage	
		Structural						Centeromeric				Numerical			%	Mean $\pm$ S.E.
		Ring	Breaks	Gap	Deletion	Stick	End to end association	Fragment	Pulverized	Hypoploidy	Polyploidy	No.				
control	500	--	1	--	4	3	--	1	--	1	--	1	--	10	2	10.1 $\pm$ 0.21
a	500	1	1	--	3	1	2	1	--	3	--	12	--	12	2.4	12.05 $\pm$ 0.50
b	500	2	1	--	3	1	1	1	--	2	--	11	--	11	2.2	11.50 $\pm$ 0.34



**Fig. (1) :** A) Uterus of a pregnant rat (control), note the complete number of foeti that are normal in size. B) Uterus of a pregnant rat given the therapeutic dose of doramectin showed early foetal resorption. C) Uterus of a pregnant rat given the double dose of doramectin showed early foetal resorptions. D) Uterus of a pregnant rat given the double dose of doramectin showed late foetal resorption.



**Fig. ( 2):** A)Cross section in the head of the rat foeti from dams given double dose of doramectin subcutaneously at 6<sup>th</sup> day of gestation period. Notice hemorrhage in the brain. B) Cross section in the kidney showing slight widening of the renal pelvis compared with a control(a). C) Cross section in the heart ventricles disclosing thickening of the ventricular wall of the heart compared with a control(a). D) Rat foeti from dams given therapeutic and double dose of dorameetin injected subcutaneously at 6<sup>th</sup> day of gestation period showing normal complete skeleton as a control group (a).



**Figure (3):** (a) Metaphase spread obtained from femur bone marrow culture of control pregnant rat. (b) Metaphase spread obtained from suckling neonates naturally delivered from female rats given therapeutic dose showing normal chromosomal structure. (c) Metaphase spread of pregnant rat administered the double dose of showing ring and sticky chromosomes. (d) chromosome break and gap. (e) Pulverization. (f) chromosome break, deletion and sticky chromosomes .

## REFERENCES

**All, A.; Fahmy, F. M. and Edress, M. Nareman. (1988)** : Pathological and clinico-Pathological studies on antiparasitic drug "Ivermectin" toxicosis in albino rats. Zg. Vet. J. 16(14): 19-31.

**Barcellona, P. S.; Fanelli, O. and Campana, A. (1977)** : Teratological studies of etoperidone in the rat and rabbit. Toxicol., 2:87-94.

**Cohen, R. L. (1966)** : Experimental chemoteratogenesis. Adv. Pharmacol., 4: 263-334.

**Gad N. A. Gehan, (1992)** : Effects of ivermectin on female fertility. Thesis, Presented to Faculty of Vet. Med., Zag. University.

**Genest, P. and Auger, C. (1963)** : Observations on the technique for the study of human chromosomes by the culture of leukocytes from peripheral blood. Can. Med. Assoc. J., 88: 302.

**Hayes, A. W. (1988)** : Principles and methods of toxicology 2nd ed., pp. 320-359. Raven Press, New York.

**Jayakumar K.; Honnegowda; Glori Doss R. G. (1999)** : Efficacy of doramectin, a new antihelminthic endectocides in scabies in rabbits, Indian Journal of pharmacology : 31, 265 .

**Kopf, R. And Salewski, S. D. (1964)** : Chemoteratogenesis. Arch. Expt. Pathol. Pharmacol., 274. 367.

**Lankas, R. G. and Gordon, L. R. (1989)** :

Toxicology. In Ivermectin and Abamectin. Campbell, W. C., Ed. Springer Verlag, New York, NY, 10-142.

**Lankas, R. G.; Minsker, H. D. And Robertson, T. R. (1989)** : Effects of ivermectin on reproduction and neonatal toxicity in rats. Fd. Chem. Toxic. 27 (8): 523- 529.

**Lubchenco, L. O. (1970)** : Assessment of gestational age and development at birth. Ped. Clin. N.A.17:125-145.

**Molyneux D. H.; Bradley M.; Hoerauf A.; Kyelem D. and Taylor M. J. (2003)** : Mass drug treatment for lymphatic filariasis and onchocerciasis. Trends Parasitol.: 19. 516-522.

**Paget, S. and Barnes, R. (1964)** : Evaluation of drug activities, pharmacometrics, eds. Laurence and Bachrach, Vol. 1., Academic Press, New York.

**Persaud, T. V. N. and Henderson, W. M. (1969)** : The teratogenicity of barbital sodium in mice. Brug Res. 19 : 1309-1310.

**Poul, J. M. (1988)** : Effects of prenatal ivermectin exposure on behavioral development of rats. Neurotoxicity and teratology. 10 (3) :267-272.

**Snell, K. (1982)** : Developmental toxicology. Croom Helm. LTd., London P14.

**Tuchman-Duplicsis, H. (1975)** : Drug effects on the foetus. Publishing Sciences Group Inc. Acton. Mass.

**Yosida, T. H. and Amano, K. (1965) :** Autosomal polymorphism in laboratory bred and wild norway rats. *Rattus norvegicus* found in Misima. *Chromosoma*, 16: 658-667.

## الملخص العربي

### تأثير الدورامكتين على التطور الجنيني فى الفئران

د / مجدى عامر

د / محمد جبر

د / چيهان جاد\*

د / رشا عبدالجليل

نم الأدوية - كلية الطب البيطرى - جامعة المنصورة

معهد بحوث صحة الحيوان - الزقازيق\*

يعتبر عقار الدورامكتين من أقوى العقاقير القاتلة للديدان والطفيليات المفصليّة فى الحيوانات المختلفة كما أن له تأثير واسع المجال على مختلف أنواع الديدان خاصة الديدان الإسطوانية، وعلى الرغم من ذلك فإن عقار الدورامكتين يتم إخراجه فى اللبن كما أنه يعبر الحاجز المشيمى للأمهات، لذلك أجرى هذا البحث لدراسة مدى سمية عقار الدورامكتين على إناث الفئران البيضاء والأجنة حيث تم دراسة التشوهات الجنينية والكروموسومية وفحص الهياكل العظمية والأعضاء الداخلية للأجنة وذلك بعد حقن الأمهات بالجرعة العلاجية وضعفها فى اليوم السادس من الحمل.

وقد أظهرت النتائج أن استخدام الجرعة العلاجية من العقار يعتبر آمن، إلا أن استخدام ضعف الجرعة العلاجية أدى إلى حدوث بعض التشوهات فى الأعضاء الداخلية كما أدى إلى حدوث تشوهات كروموسومية لذا ننصح باستخدام الجرعة العلاجية فى الحيوانات العشار لتجنب أى تأثيرات ضارة محتملة على الأجنة.